

Case report

Open Access

Acute scrotum as a complication of Thiersch operation for rectal prolapse in a child

Mohammad M Saleem and Hashem Al-Momani*

Address: Department of Pediatric Surgery, Jordan University Hospital P.O. Box 13546, Amman 11942, Jordan

Email: Mohammad M Saleem - mohomari@hotmail.com; Hashem Al-Momani* - hashemmomani@yahoo.com

* Corresponding author

Published: 28 December 2006

Received: 11 August 2006

BMC Surgery 2006, 6:19 doi:10.1186/1471-2482-6-19

Accepted: 28 December 2006

This article is available from: <http://www.biomedcentral.com/1471-2482/6/19>

© 2006 Saleem and Al-Momani; licensee BioMed Central Ltd.

This is an Open Access article distributed under the terms of the Creative Commons Attribution License (<http://creativecommons.org/licenses/by/2.0>), which permits unrestricted use, distribution, and reproduction in any medium, provided the original work is properly cited.

Abstract

Background: We report a case of acute scrotal condition that presented in a four year old male child one year after being treated for an idiopathic rectal prolapse utilizing Thiersch wire.

Case presentation: The acute scrotum had resulted from spreading perianal infection due to erosion of the circlage wire. The condition was treated with antibiotics and removal of the wire. The child made an uneventful recovery.

Conclusion: This case highlights that patients with Thiersch wire should be followed until the wire is removed. Awareness of anal lesions as a cause of acute scrotal conditions, and history and physical examination are emphasized.

Background

Acute scrotum is a surgical emergency. Causes are usually intra scrotal conditions, of which torsion of the testis is the most important. Less common causes are extra scrotal in origin, namely idiopathic scrotal edema. Anal conditions are rare causes of acute scrotum. Diagnosis sometimes may be very difficult without surgical exploration. Careful history taking and physical examination including perianal region is emphasized.

Case presentation

B.S. a 4-year-old male child was admitted to the pediatric surgical ward at Jordan University Hospital because of two days history of swelling, redness and pain of his scrotum (Fig. 1). There was no history of trauma. The pain was moderate, not characteristic of torsion, and not the chief complaint. Oral temperature was 37.8°C and pulse 94/min. Physical examination revealed bilateral red swollen scrotum, moderately hot and tender allowing examination of the testes, which were in normal position and of

equal size and not tender. There was a small amount of fluid bilaterally detected on transillumination. The rest of the physical examination was unremarkable. Laboratory work up showed Hb. 10.5 gm/dl, Hct. 32%, WBC $12.7 \times 10^3/\text{mm}^3$ and normal serum amylase. Ultrasound examination confirmed the equal sized testes, with normal echogenicity, the presence of small amount of fluid in the scrotum, and the edematous scrotum. On further examination of the scrotum, a streak of redness extended along the midline raphe to the perineum, where a visible wire through an eroded perianal skin was seen (Fig 2). The patient underwent a Thiersch wire insertion for a rectal prolapse one year before. The patient was started on broad-spectrum antibiotics (Ampicillin, Gentamycin and Metronidazol). It was decided that the Thiersch wire has to be removed in theatre under general anesthesia. While examination under anesthesia the perineum appeared healthy, without signs of inflammation, or suppuration but moderate amount of induration. Rectal exam was normal; there was moderate narrowing and fibrosis at the

anal verge. After removal of the wire the tract was intact with minimal discharge, which cleared in few days following wire removal. The sinus tract was very short lived and closed without any problems thereafter.

Culture taken from the site of the wound grew streptococcus fecalis sensitive to the administered antibiotics. The scrotal swelling and redness subsided gradually. The child was discharged without any complications. Follow up was uneventful for both the scrotal redness and swelling as well as the rectal prolapse.

Discussion

Common causes of acute scrotum at the age of four years are torsion of the testis or its appendix and incarcerated hernia. Less common causes are idiopathic scrotal edema and vasculitis (Henoch-Schonlein purpura). Rare causes are of anal pathology. Idiopathic scrotal edema was suggested by Nicholas et al to be of anal pathology origin [1]. Nour and MacKinnon reported ten cases out of 143 cases of acute scrotum were due to anal pathology [2].

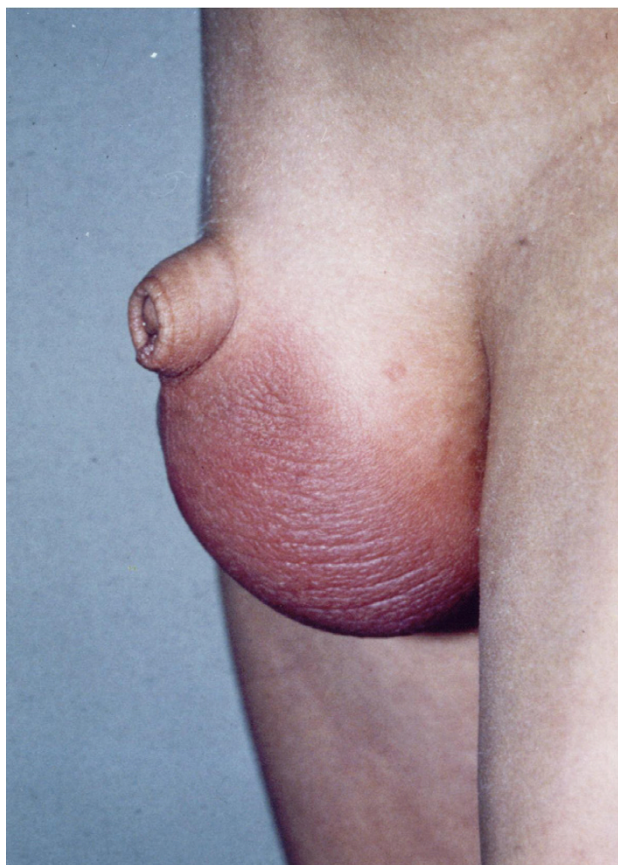


Figure 1
The child's scrotum. Note the redness and fullness of both scrotal compartments.

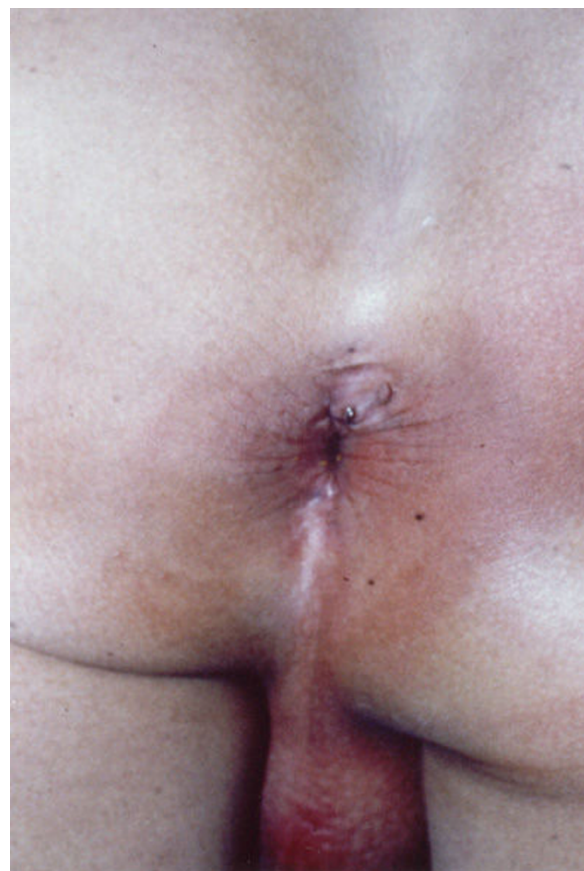

Figure 2
Thiersch's wire is shown eroding through the perianal skin.

The exact diagnosis of acute scrotum is very difficult in spite of available diagnostic means. The majority of cases require surgical exploration to rule out a testicular torsion. Careful history taking and physical examination can, as in this case, save the child from an operation.

Rectal prolapse in children is the result of self-limiting underlying disease, such as diarrhea, constipation, and weight loss [3]. Minor corrective procedures are injection of sclerosing agent [4,5], such as alcohol [6], phenol [7], or hypertonic saline[8] into the submucosa, cauterization of mucosa or anal encirclement according to the Thiersch-Ombredanne or its modification [8-10]. Each has its own advantages and recurrence rate. The advantages of the Thiersch operation are simplicity, effectiveness, and safety. The disadvantages are poor tolerance, rigidity, breakage and infection. Infection has always been described as local and superficial. As a matter of fact the principle of Ekehorn's operation for rectal prolapse is based on perirectal infection to prevent the rectum from prolapse by the formation of adhesions between the rectum and the surrounding structures [11]. Infection has

also been reported after a Dacron prosthesis was used instead of wire, necessitating its removal [9]. Perineal clostridial myonecrosis has been described as a complication of Thiersch operation [12]. In the case we have reported the complication resulted from long standing wire acting as a hard foreign body that eroded the overlying skin resulting in perineal wound infection. Spreading of the infection may be related to the characteristics of the bacteria involved or because of shared lymphatic drainage. This case adds to the spectrum of the anal pathologies that may lead to scrotal infection. Awareness of such a complication, as well as close follow up of patients and a high degree of suspicion are the key to successful management.

Conclusion

This case highlights that patients with Thiersch wire should be followed until the wire is removed. Awareness of anal lesions as a cause of acute scrotal conditions, and history and physical examination are emphasized

Competing interests

The author(s) declare that they have no competing interests.

Authors' contributions

Both authors, M.M.S, and H.M.A contributed equally to the case, and both have read and approved the manuscript

Acknowledgements

Consent has been obtained

References

- Nicholas JL, Morgan A, Zachary RB: **Idiopathic oedema of scrotum in young boys.** *Surgery* 1970, **67**:847-850.
- Nour S, MacKinnon AE: *J R Coll Surg Edinb* 1991, **36**:392-394.
- Zempsky WT, Rosenstien BJ: **The cause of rectal prolapse in children.** *Am J dis Child* 1988, **142**:338-339.
- Schepens MA, Verhelst AA: **Reappraisal of the Ekehorns rectopexy in the management of rectal prolapse in children.** *J Ped Surg* 1993, **28(11)**:1494-1497.
- Malyshev Y, Gulin V: **Our experience with the treatment of rectal prolapse in infants and children.** *Am J Proctol* 1973, **24**:270-272.
- Wyllie G: **The injection treatment of rectal prolapse.** *J Ped Surg* 1979, **14**:62-64.
- Kay N, Zachary R: **The treatment of rectal prolapse in children with injection of 30% saline solution.** *J Ped Surg* 1970, **5**:334-337.
- Thiersch C: **Carl Thiersch 1822-1895. Concerning prolapse of the rectum with special emphasis on the operation by Thiersch.** *Dis Colon Rectum* 1988, **31(2)**:154-155.
- Khanduja KS, Hardy TG jr, Aguilar PS, Plasencia G, Hartman RF, Bowers F, Stewart WR: **A new silicone prosthesis in the modified Thiersch operation.** *Dis Colon Rectum* 1988, **31(5)**:380-383.
- Larach SW, Vazquez B: **Modified Thiersch procedure with silastic mesh implant: a simple solution for fecal incontinence and severe prolapse.** *South Med J* 1986, **79(3)**:307-309.
- Poole GV Jr, Pennell TC, Myers RT, Hightower F: **Modified Thiersch operation for rectal prolapse. Technique and results.** *Am Surg* 1985, **51(4)**:226-229.
- Rye BA, Seidelin C, Dueholm S: **perineal myonecrosis following Thiersch operation for rectal prolapse.** *Ann Chir Gynaecol* 1987, **76(2)**:136-7.

Pre-publication history

The pre-publication history for this paper can be accessed here:

<http://www.biomedcentral.com/1471-2482/6/19/prepub>

Publish with **BioMed Central** and every scientist can read your work free of charge

"BioMed Central will be the most significant development for disseminating the results of biomedical research in our lifetime."

Sir Paul Nurse, Cancer Research UK

Your research papers will be:

- available free of charge to the entire biomedical community
- peer reviewed and published immediately upon acceptance
- cited in PubMed and archived on PubMed Central
- yours — you keep the copyright

Submit your manuscript here:
http://www.biomedcentral.com/info/publishing_adv.asp

